

Ankyloblepharon Filiforme Adnatum

Avi Rubinov MD¹, Nir Seider MD^{1,2}, Eedy Mezer MD^{1,2}, Liron Berkovitz MD¹, Eytan Z. Blumenthal MD¹ and Imad R. Makhoul MD PhD^{2,3}

Departments of ¹Ophthalmology and ²Pediatrics and Neonatology, Rambam Health Care Campus, Haifa, Israel

³Affiliated with Rappaport Faculty of Medicine, Technion-Israel Institute of Technology, Haifa, Israel

KEY WORDS: ankyloblepharon filiforme adnatum (AFA), pediatric ophthalmology, neonatology

IMAJ 2014; 16: 000–000

Bilateral multiple fibrous tissue bands bridging the lids were identified upon the birth of a Caucasian male born at 40 weeks of gestation following a spontaneous vaginal delivery and uneventful pregnancy. Physical examination including inspection of the anterior segment of the eyes through the fibrous bands did not reveal any abnormal findings. This rare congenital anomaly is known as ankyloblepharon filiforme adnatum (AFA) and can exist as an isolated finding or as part of well-defined syndromes.

AFA describes a single or multiple bands of fibrous tissue joining the upper and lower eyelids either unilaterally or bilaterally. These connecting strands were found to consist of a vascularized central core surrounded by stratified squamous epithelium [1]. The bands consistently arise from the

grey line, located between the meibomian gland orifice line and the eyelash line. During normal prenatal development the eyelids remain fused until the fifth month of gestation; in some cases they may not separate completely until as late as the seventh month in utero.

AFA may be associated with iridogoniodysgenesis, often complicated by juvenile glaucoma [2]. Systemic associations include trisomy 18 (Edward's syndrome) [3], Hay-Wells syndrome [4], the popliteal pterygium syndrome (with intracural webbing of the lower limbs), and CHAND syndrome (acronym for curly hair, ankyloblepharon, nail dysplasia). Other rare associations include hydrocephalus, meningocele, imperforate anus, bilateral syndactyly, and structural cardiac defects such as patent ductus arteriosus and ventricular septal defect [5].

Surgery to free these adhesions should be performed as soon as possible to prevent the risk of occlusion amblyopia (amblyopia secondary to reduced visual stimuli). The fibrous bands were severed using a squint hook and scissors and then trimmed at their insertion to the grey line.

The images show the right and the left eye just before the surgery [Figures 1A and 2A] and immediately after [Figures 1B and 2B]. The following day an ocular examination including a dilated fundus examination did not reveal any additional abnormalities.

The prompt recognition and treatment of AFA in the newborn is critical to prevent deep amblyopia and to rule out possible rare systemic abnormalities.

Correspondence

Dr. A. Rubinov

29/19 Keren Hayesod Street, Haifa 3497029, Israel
email: avi@rubinov.com

References

1. Judge H, Mott W, Gabriels J. Ankyloblepharon filiforme adnatum. *Arch Ophthalmol* 1929; 2: 702-8.
2. Scott MH, Richard JM, Farris BK. Ankyloblepharon filiforme adnatum associated with infantile glaucoma and iridogoniodysgenesis. *J Pediatr Ophthalmol Strabismus* 1994; 31 (2): 93-5.
3. Bacal DA, Nelson LB, Zackai EH, Lavrich JB, Kousseff BG, McDonald-McGinn D. Ankyloblepharon filiforme adnatum in trisomy 18. *J Pediatr Ophthalmol Strabismus* 1993; 30 (5): 337-9.
4. Long JC, Blandford SE. Ankyloblepharon filiforme adnatum with cleft lip and palate. *Am J Ophthalmol* 1962; 53: 126-9.
5. Gruener AM, Mehat MS. A newborn with ankyloblepharon filiforme adnatum: a case report. *Cases J* 2009; 2: 8146.

Figure 1. [A] Right eye AFA
[B] The same eye following the surgical procedure

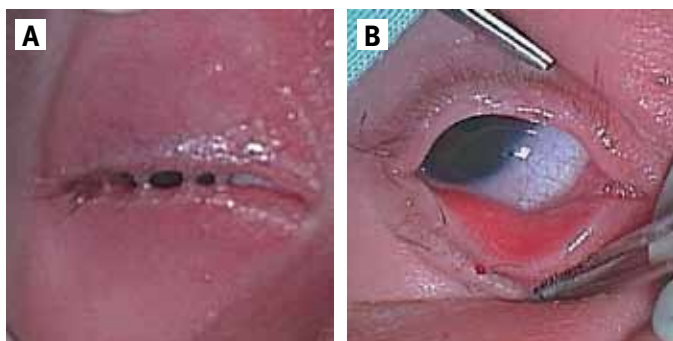


Figure 2. [A] Left eye AFA
[B] The same eye following the surgical procedure

