

Bilateral Traumatic Optic Neuropathy in an Unconscious Patient: A Diagnostic Challenge

Gilad Allon MD¹, Nir Seider MD^{1,2}, Eytan Z. Blumenthal MD^{1,2} and Itzhak Beiran MD^{1,2}

¹Department of Ophthalmology, Rambam Health Care Campus, Haifa, Israel

²Rappaport Faculty of Medicine, Technion-Israel Institute of Technology, Haifa, Israel

KEY WORDS: optic neuropathy, trauma, unconsciousness, visual loss, bilateral involvement

IMAJ 2014; 16: 516–517

Traumatic optic neuropathy is the result of an indirect optic injury caused by a contusion necrosis of the nerve fibers related to the shearing forces generated during the trauma, especially in the intracanalicular part of the optic nerve. TON may be a consequence of a relatively mild injury, especially in the case of trauma to the forehead region. TON usually causes immediate and severe visual loss which is unilateral in most cases [1].

In retrobulbar TON the optic disk appears normal at onset and atrophies within 4–8 weeks. In unilateral cases the affected eye demonstrates a relative afferent pupillary defect. Transethmoidal optic canal decompression and/or high dose intravenous corticosteroids were suggested as possible treatments for TON, in addition to follow-up. The International Optic Nerve Trauma study, a non-randomized multicenter comparative analysis of treatment outcomes, did not demonstrate a beneficial effect of either of these treatments [2,3]. The Corticosteroid Randomization After Significant Head Injury (CRASH) study included over 10,000 head injury victims. The study compared the effect of high dose corticosteroids administered within 8 hours of the trauma compared to placebo. The study was aborted because the group

treated with corticosteroids was found to have a statistically significant higher mortality rate compared to the placebo group [4]. This means that not only is the treatment with high dose corticosteroids not beneficial in cases of TON, it may in fact be harmful when given to patients with severe head trauma and brain injury.

We present the case of a patient with bilateral TON. Bilateral TON is far less common than unilateral TON but is more meaningful functionally due to the likelihood of severe bilateral visual loss as its final outcome. In this case the diagnosis was difficult because the patient was anesthetized and could not verbalize his visual loss following the trauma and visual acuity could not be examined.

Bilateral involvement is not typical of traumatic optic neuropathy and is more commonly seen in other optic neuropathies such as arteritic optic neuropathy, infectious optic neuropathy in children, and toxic optic neuropathy [5].

PATIENT DESCRIPTION

A 75 year old Caucasian man experienced direct head, face and chest injury upon falling forward after stumbling on a low fence. His past medical history included lymphoma in full remission for 10 years and no other known ocular or systemic pathologies.

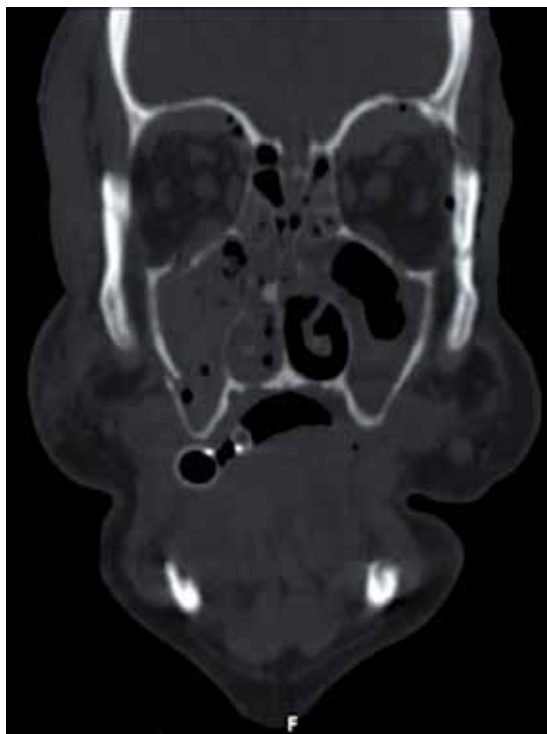
The patient arrived at the trauma unit 30 minutes after the fall. Gross neurologic examination was normal except for dilated unresponsive pupils. The patient was anesthetized and ventilated because of restlessness and nose-bleeding. Computed tomography revealed a subarachnoid hemorrhage without a mass effect. Chest

radiograph showed stable lymphadenopathy and a large volume of pleural effusion. A chest drain was inserted into the right pleural cavity. Blood analysis, including complete blood count, clotting function, electrolytes, glucose, renal function, liver function, erythrocyte sedimentation rate and C-reactive protein, showed that all were within normal limits.

Ophthalmic evaluation 4 hours following the trauma, conducted while the patient was anesthetized and ventilated, revealed a deep laceration above the right eyebrow and normal intraocular pressure bilaterally as measured by palpation. Forced duction test was impossible because of soft tissue swelling. Bilateral periorbital hematomas, subconjunctival hemorrhage and chemosis were observed. Both pupils were 8 mm wide and unresponsive to light. The anterior segments of both eyes were otherwise within normal limits. Fundus examination was normal. Head CT showed bilateral medium-sized subperiosteal hematomas in the upper anterior orbits, right orbital floor fracture, left orbital lateral wall fracture and left orbital floor fracture. The eyeball and optic nerve were intact bilaterally. Air in the orbits was found adjacent to all fractures. The hematomas and the air did not compress the optic nerves [Figure].

Ophthalmic evaluation following extubation and cessation of anesthesia 4 days after the original trauma revealed visual acuity of no light perception in both eyes. The intraocular pressure was 15 mmHg in both eyes. Eye movements were full and normal in all directions of gaze in both eyes. Periorbital hematomas, subconjunctival hemorrhages, clear corneas and nor-

TON = traumatic optic neuropathy



Head CT demonstrates subperiosteal hematomas and orbital fractures

mal depth clear anterior chambers were observed in both eyes. Both eyes demonstrated maximal mydriasis unresponsive to light and accommodation. Lenses were clear and fundus examinations appeared normal bilaterally. Magnetic resonance imaging examination showed bilateral subperiosteal hematomas in the upper part of the orbits without signs of optic nerve compression. Visual evoked potential showed no visual potentials in response to light stimulation.

The patient was diagnosed with bilateral TON. There was no contact between the hematomas and the nerve, and there was no direct compression on the nerve. The injury was facial, similar to previous reports of TON.

COMMENT

The differential diagnosis of post-traumatic bilateral severe visual loss includes

cavernous sinus syndrome and cortical blindness, both of which show typical findings on CT. The CT assists in early diagnosis in the emergency room.

Bilateral severe injury to both optic nerves is a rare event. The case presented here should alert physicians to this rare possibility. Early diagnosis may be beneficial in allowing early treatment in the future. In victims of severe head trauma unable to undergo a visual acuity test a high index of suspicion is the key for early diagnosis.

VEP results confirm the presence of optic neuropathy, while MRI results rule out other possible causes for the observed optic nerve damage. MRI may imply TON by demonstrating facial, intracranial and intraorbital injuries.

Bilateral TON is a rare condition with only a few cases reported in the literature [2]. Bilateral TON should be considered in

VEP = visual evoked potential

the differential diagnosis of post-traumatic blindness, even in a case of relatively minor trauma.

No signs on physical examination are expected in the early phase apart from bilateral mydriasis. If TON is suspected and the patient's cooperation is limited, early MRI and VEP studies are indicated. RAPD (relative afferent pupillary defect) examination can provide the diagnosis in the case of unilateral TON; however, this exam is not possible in bilateral TON because the pupils are dilated and not responsive to light.

In an unconscious patient with bilateral TON, decisions are much more complicated. Treatment of TON with steroids is strictly contraindicated in cases where severe head trauma accompanies the ocular damage. In cases without head trauma steroid treatment may be applied, although its benefit is questionable. Further research is required to establish the appropriate treatment approach for this condition.

Correspondence

Dr. G. Allon
 Dept. of Ophthalmology, Rambam Health Care Campus, Haifa 31906, Israel
Phone: (972-4) 854-2668
Fax: (972-4) 854-2142
email: drgiladallon@gmail.com

References

1. Carta A, Ferrigno L, Salvo M, Biachi-Marzoli S, Boschi A, Carta F. Visual prognosis after indirect traumatic optic neuropathy. *J Neurol Neurosurg Psychiatry* 2003; 74 (2): 246-8.
2. Levin LA, Beck RW, Joseph MP, Seiff S, Kraker R. The treatment of traumatic optic neuropathy: the International Optic Nerve Study. *Ophthalmology* 1999; 106 (7): 1268-77.
3. Cook MW, Levin LA, Joseph MP, Pinczower EF. Traumatic optic neuropathy. A meta-analysis. *Arch Otolaryngol Head Neck Surg* 1996; 122 (4): 389-92.
4. Edward P, Arango M, Balica L, et al., CRASH trial collaborators. Final results of MRC CRASH, a randomized placebo-control trial of intravenous corticosteroids in adults with head injury – outcomes at 6 months. *Lancet* 2005; 365: 1957-9.
5. Pillar G, Toubi E. Vaccination-induced bilateral optic neuritis: rare but existing. *IMAJ* 2012; 14 (11): 690-1.

“I learned long ago that being Lewis Carroll was infinitely more exciting than being Alice”

Joyce Carol Oates (b. 1938), American writer